

Imaging for Residents – Quiz

Coxitis with Synovial Hypertrophy

Mariam Erraoui*, Hanan Rkain, Ilham Aachari, Latifa Tahiri, Fadoua Allali

Department of Rheumatology B, El Ayachi Hospital, Sale, Morocco

SECTION 1 – QUIZ

A 27-year-old patient, with no pathological antecedent, has presented with oligoarthralgia in the left side (hip, knee, and ankle) evolving for 3 months with functional impotence, fever, and lost weight of 10 kg in 3 months. On physical examination, we found the limitation of the left heel with swelling and left ankle pain. Figure 1 shows the X-ray of the pelvis and the thorax and the ultrasound image of the hip. The blood analysis showed a sedimentation rate to 69 mm/h, a C-reactive protein to 53 mg/L without leukocytosis in peripheral blood counts.

WHAT IS THE DIAGNOSIS?

Declaration of patient consent

The authors certify that they have obtained all appropriate patient consent forms. In the form the patient(s) has/have given his/her/their consent for his/her/their images and other clinical information to be reported in the journal. The patients understand that their names and initials will not be published and due efforts will be made to conceal their identity, but anonymity cannot be guaranteed.

Financial support and sponsorship

Nil.

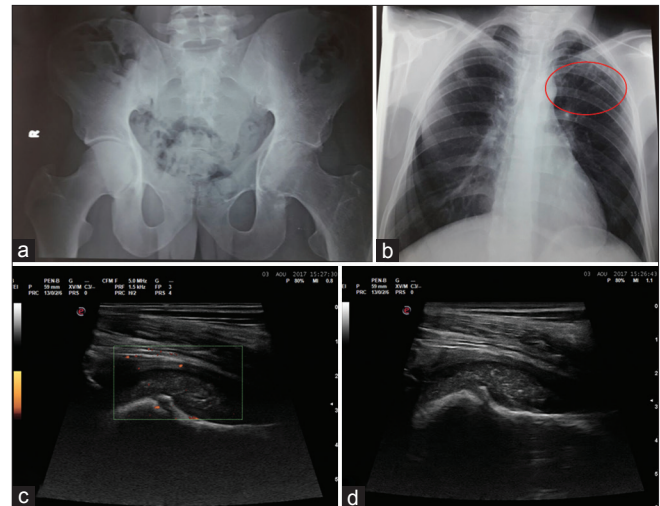


Figure 1: (a) Radiograph of pelvis showing left coxitis and condensation of sacroiliac joint (b) thoracic X-ray showing infiltration of summit (c and d) ultrasound imaging of the left hip with and without Doppler showing synovial hypertrophy

Conflicts of interest

There are no conflicts of interest.

Received: 07-09-2017 Accepted: 17-11-2017 Available Online: 12-07-2019

Access this article online

Quick Response Code:



Website:
www.jmuonline.org

DOI:
10.4103/JMU.JMU_3_18

Address for correspondence:

Dr. Mariam Erraoui,
Department of Rheumatology B, El Ayachi Hospital, Sale, Morocco.
E-mail: mariama_erraoui@yahoo.fr

This is an open access journal, and articles are distributed under the terms of the Creative Commons Attribution-NonCommercial-ShareAlike 4.0 License, which allows others to remix, tweak, and build upon the work non-commercially, as long as appropriate credit is given and the new creations are licensed under the identical terms.

For reprints contact: reprints@medknow.com

How to cite this article: Erraoui M, Rkain H, Aachari I, Tahiri L, Allali F. Coxitis with synovial hypertrophy. J Med Ultrasound 2019;27:164.